

Jonathan F. Kohan., M.D.

* 5651 Sepulveda Blvd.# 201 Sherman Oaks, CA 91411 *

Surgical Authorization Request**Current Date: 06/07/2023****Our Chart No. 20078796****Patient Name: Pepper SMITH****DOB: 05/22/1971****Claim #: 06758786****Claim #:Unassigned****Request from office Visit date: 05 30, 2023**

SCIF - LA (CLM# ENDING IN 00-49)

PO BOX 65005

Fresno, CA 93650

You can contact us by phone, fax or email.

Peer to Peer Direct line only: 818-616-1645**Phone: (818) 616-1645*****Fax: (818) 583-1717*****Email: SurgicalUR@synapseortho.com**

In accordance with 8 C.C.R. 9792.6 written authorization for the above captioned procedure is hereby requested. For clarification purposes, it is noted in 9792.6 (a) (4) "Request for authorization" means any written request for assurance that appropriate reimbursement will be made for a specific course of proposed medical treatment....' Please be advised that Dr. Haronian has financial interest in Osteon Surgery Center and Kinetic Surgery Center. Please consider this request for authorization a request for written assurance that reimbursement for the proposed procedure be made according to the usual and customary charges of the Ambulatory Surgical Center rendering service and within the timeframes set forth withing 8 C.C.R. 9792.5 and Labor Code Section 4603.2

Labor Code Section 4610, section (f) states that "no person other than a licensed physician., may modify, delay or deny request for authorization of medical treatment. Labor Code Section 4610 section (g) states the time frame for UR. (1) Prospective or concurrent decisions shall be made in a timely fashion that is appropriate for the nature of the employee's condition, not to exceed five working days from the receipt of the information reasonably necessary to make the determination, but in no event more than 14 days from the date of the medical treatment recommendation by the physician. In cases where the review is retrospective, the decision shall be communicated to the individual who received services, or to the individual's designee, within 30 days of receipt of information that is reasonably necessary to make this determination. All of the denial or medication procedures contained in Labor Code section 4610 (g) (2) and (3) are mandatory, and if the statutory requirements are not met, the utilization review report is not admissible. The only other procedure for disputing the treatment is a QME, pursuant to Labor Code section 4602.

Proof of Service State of California, County of Los Angeles

I am a resident of the county of Los Angeles; I am over the age of eighteen years and not a party to the within entitled action. My business address is: 5651 Sepulveda Blvd. Suite 201 Sherman Oaks, CA 91411 or 724 Corporate Center Drive. 2nd Floor, Pomona, CA 91768

On this date 06/07/2023 I served Request for Authorization to the above Insurance Co. SCIF - LA (CLM# ENDING IN 00-49) PO BOX 65005 Fresno, CA 93650, by transmitting via US Postal Services between the hours of 8:00am and 5:00pm. I declare under the penalty of perjury under the laws of the State of California that the foregoing is true and correct. Executed in Los Angeles, CA.


Executed on 06/07/2023 at Sherman Oaks, California.

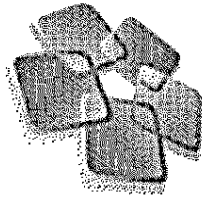
I declare under penalty of perjury that the above is true and correct.

Signature: Ivane Yu
Ivane Yu

State of California
Division of Workers' Compensation
REQUEST FOR AUTHORIZATION

DWC Form RFA - California Code of Regulations, title 8, section 9785.

This form must accompany the Doctor's First Report of Occupational Injury or Illness, Form DLSR 5021, a Treating Physician's Progress Report, DWC Form PR-2, or narrative report substantiation the requested treatment.			
<input type="checkbox"/> New Request <input type="checkbox"/> Resubmission - Change in Material Facts			
<input type="checkbox"/> Expedite Review: Check box if employee faces an imminent and serious threat this or her health			
<input type="checkbox"/> Check box if request is a written confirmation of prior oral request.			
Employee Information			
Employee Name (Last, First, Middle): SMITH,Pepper			
Date of Injury (MM/DD/YYYY): 07/31/2021;CT:7/31/2021 to 7/31/2022		Date of Birth(MM/DD/YYYY): 05/22/1971	
Claim Number: 06758786;Unassigned		Employer: State of California Betty T Yee State	
Provider Information			
Provider Name:Jonathan F. Kohan.M.D.			
Peer to Peer Direct line: 818-616-1645		Contact Name:	
Address: 5651 Sepulveda Blvd.# 201	City: Sherman Oaks	State: CA	
Zip Code: 91411	Phone: 818-616-1645	Fax Number: 818-583-1717	
Provider Specialty: Pain Management		NPI Number: 1093727109	
Claims Administrator Information			
Claims Administrator Name: SCIF - LA (CLM# ENDING IN 00-49)		Contact Name:Kim, James	
Address: PO BOX 65005	City: Fresno	State: CA	
Zip Code: 93650	Phone:888-782-8338	Fax Number: 707-646-0738	
E-mail Address:			
Requested Treatment (see instruction for guidance; attached additional pates if necessary)			
Either state the requested treatment in the below space or indicate the specific page number(s) of the accompanying medical report on which the request treatment can be found. Up to five (5) procedures may be entered; attached additional request on a separate sheet.			
Diagnosis	M54.2 Cervical Pain M75.40 Impingement syndrome, shoulder M77.10 Lateral epicondylitis, elbow G56.00 Carpal tunnel syndrome		
ICD-Code			
Procedure Requested	Request for Authorization: Cervical Epidural Injection C6-7.		
CPT/HCPCS Code			
Other Information: (Frequency, Duration, Quantity, Facility, etc.)			
Treating Physician Signature: 			Date:06/07/2023
Claims Administrator Response			
<input type="checkbox"/> Approved <input type="checkbox"/> Denied or Modified (see separate decision letter <input type="checkbox"/> Delay (See separate notification of delay)			
<input type="checkbox"/> Requested treatment has been previously denied <input type="checkbox"/> Liability for treatment is disputed			
Authorization Number (if assigned):		Date:	
Authorized Agent Name:		Signature:	
Phone:	Fax Number:	E-mail Address:	
Comments:			



Jonathan F. Kohan, M.D.

DIPLOMATE, AMERICAN BOARD
OF ANESTHESIOLOGY
AMERICAN ACADEMY
OF PAIN MEDICINE

INTERNATIONAL ASSOCIATION
FOR THE STUDY OF PAIN
NORTH AMERICAN SPINE SOCIETY

CHRIS BLANCHFIELD, PA
MICHAEL NADZHAFOV, PA, MPH
ZIMIAN JANG QI, PA-C, MSPA, CST
JARED TOLLER, PA

5651 SEPULVEDA BLVD, SUITE 201
SHERMAN OAKS, CA 91411
PH. (818) 788-2400
FX. (818) 788-2453

724 CORPORATE CENTER DR
2ND FLOOR
POMONA, CA 91768
PH. (909) 622-6222
FX. (909) 622-6220

5211 E WASHINGTON BLVD STE 18
COMMERCE, CA 90040
PH. (818) 788-2400
FX. (818) 788-2453

WWW.JKOHAN.COM

Patient Name : Pepper Smith
Date of Service : May 30, 2023
Claim # : 06758786
Employer : State of California Betty T Yee State
Date of Birth : May 22, 1971
Date of Injury : 07/31/2021
CT:7/31/2021 to 7/31/2022
File # : 20078796

SECONDARY PHYSICIAN PAIN MANAGEMENT FOLLOW-UP REPORT AND REQUEST FOR AUTHORIZATION

This special narrative report is reimbursable (1994) Official Medical Fee Schedule because one of the following: There was an unexpected or significant change in the patient's condition or the treatment plan; there is a change in patient care or status; submitted records were reviewed or specific questions were answered.

Ms. Pepper is a very pleasant female who presents with complaint of a chronic pain in the neck and the left shoulder. The patient continues to work. She saw medical-legal examiner several days ago, report is pending. She is scheduled to have yet another one.

We did request authorization for the cervical epidural injection without any progress. The patient is using ibuprofen gel, naproxen, Prevacid, and lidocaine ointment. With medications, she is more functional and would like to have a refill today.

Unfortunately, there has been no progress with the requested cervical epidural injection and we do not have any information about denial or approval.

PHYSICAL EXAMINATION:

On physical examination, spasm and tenderness is noted in the paravertebral muscles of the cervical spine. Discomfort with pain is noted on abduction of left shoulder against the gravity. Decreased sensation is noted in C6 and C7 dermatomal distributions bilaterally more so on the right side. Muscle strength is 4/5 on flexion of the right

Smith, Pepper
May 30, 2023
Page 2 of 4

elbow.

DIAGNOSES:

Bilateral wrist sprain/strain with potential de Quervain's tenosynovitis and carpal tunnel syndrome.

Bilateral medial epicondylitis.

Bilateral shoulder sprain/strain with impingement on the left.

Cervical radiculopathy.

RECOMMENDATION:

Level C5-C6 is noticeable for the abutment of the right exiting nerve root. Disc deformity is 2.7 mm, right neural foraminal narrowing is noted. Uncovertebral joint hypertrophy is noticed. Level C6-C7 is noticeable for the 3.1 mm disc deformity and left uncovertebral joint hypertrophy. It does correlate with the patient's failed course of conservative treatment and clinical presentation. Thus, based on reasonable medical probability, the patient does meet criteria set by MTUS guidelines for cervical epidural injection. We are formally requesting authorization for midline cervical epidural injection at level C6-C7 targeting level C5-C6. Level C6-C7 is the highest level to do the injection safely. It will be done under the guidance of fluoroscopy.

We will arrange to obtain the report of medical-legal examiner for our records. We also would like to refill the medications today as they cause no side effect and help to maintain functional capacity.

Her next appointment will be in six weeks to re-assess clinical efficacy of medications and review medical records. Work status will be deferred.

I hope the above information has been helpful to you and if I can provide you with any further information, please do not hesitate to contact my office.

We are requesting that all the patient medical records, related or unrelated to this case be sent to our attention for review which will be incorporated in accessing the treatment and medical legal issues.

I declare, under penalty of perjury, that I have not violated the provisions of California Labor Code 139.3 and that the contents of this report and attached billing are true and correct to the best of my knowledge. I also affirm that I have not violated any sections of Labor Code 4628. Please see attached itemized billing with ICD-10 diagnosis code(s). The foregoing declaration is executed on the date of this report and signed by myself in the County of Los Angeles.

To complete this examination I have been assisted, as needed, for taking histories, taking x-rays, assisting with the patient, transcription of reports by some or all of the following personnel Alma Azucar, Natasha Yokum, Jason Perez and Emily Shemwell. Sherry Leoni, DC, may also have assisted in compiling and editing of this report. If

Smith, Pepper
May 30, 2023
Page 3 of 4

required an interpreter was provided. All of the above individuals are qualified to perform the described activities by reason of individual training or under my direct supervision.

Please be advised that Dr. Kohan has a financial interest in the Pacific Anesthesia Group.



Michael Nadzhafov, P.A.C, M.P.H.

June 2, 2023

Date



Jonathan F. Kohan, M.D.
Diplomate American Board of
Anesthesiology
Fellowship-Trained in Pain
Medicine

Eric Gofnung, DC
**6221 Wilshire Blvd. #604 {By Fairfax}
Los Angeles, CA 90048

*Workers Defenders Law Group
8018 E. Santa Ana Cny #100-215
Anaheim Hills, CA 92808

*SCIF - LA (CLM# ENDING IN 00-49)
PO BOX 65005
Fresno, CA 93650
Attn: James Kim

PROOF OF SERVICE
STATE OF CALIFORNIA

Smith, Pepper
May 30, 2023
Page 4 of 4

I am employed in the County of Los Angeles. I am over the age of 18 and not a party to the within action; my business address is:

5651 SEPULVEDA BLVD., SUITE 201, SHERMAN OAKS, CA 91411

On 6/6/2023 served the foregoing document described as:

JONATHAN F. KOHAN, M.D.
EVALUATION REPORT

Patient Name: Pepper Smith
File Number: 20078796
Claim #: 06758786
DOS: 5/30/2023

On all interested parties in this action by electronic transmission a true copy of this narrative report from **5651 SEPULVEDA BLVD., SUITE 201, SHERMAN OAKS, CA 91411**

Addressed as follows:

Eric Gofnung, DC
6221 Wilshire Blvd. #604 {By Fairfax}
Los Angeles, CA 90048

Workers Defenders Law Group
8018 E. Santa Ana Cny #100-215
Anaheim Hills, CA 92808

James Kim
SCIF - LA (CLM# ENDING IN 00-49)
PO BOX 65005
Fresno, CA 93650

I declare that I am over the age of 18 years and not a party to this action. I also declare under penalty of perjury that the foregoing is true and correct and that this declaration was executed on 6/6/2023 at



Emily Shemwell

FAX



To: . HARONIEN
Fax: 8187882453
Phone:

From: OneSource Medical Diagnostics
Fax: 877-370-5458
Phone: 877-674-8888

NOTES:

Thank you for your Business.

Contact Information

Phone: 877-674-8888 | Fax : 877-370-5458

Direct Dept Contact

Scheduling | referrals@expertmri.com
Medical Records | medicalrecords@expertmri.com
Billing | billing@expertmri.com
Lien Reductions | collections@expertmri.com

IMPORTANT WARNING: The information in this fax transmission may contain confidential health information that is privileged and legally protected from disclosure by the Health Insurance Portability and Accountability Act (HIPAA). This information is intended only for the use of the individual(s) or entity named in the document(s). If you are not the intended recipient, you are hereby notified that reading, disseminating, disclosing, distributing, copying, acting upon or otherwise using the information contained in this fax is strictly prohibited. If you have received this information in error, please notify the sender immediately.



Location: BEVERLY HILLS

PATIENT NAME : SMITH PEPPER

PATIENT ID : A158209

D-O-B : 05-22-1971

ACCESSION NO : A334088

STUDY DATE : 10-25-2022

REFERRING PHYSICIAN : GOFNUNG ERIC

APPROVAL DATE : 10-26-2022

RADIOLOGIST : ANDREW THIERRY

TO SPEAK TO A RADIOLOGIST: 877-939-7378

MRI OF CERVICAL SPINE

TECHNIQUE: Multiplanar, multisequence MRI of the cervical spine and craniocervical junction were performed without contrast in neutral position.

CLINICAL HISTORY: Pain.

FINDINGS:

Patient position: Images are evaluated in the neutral position.

Spondylolisthesis: Grade I posterior listhesis of C4 on C5.

Curvature: Straightening of the cervical lordosis.

Modic changes: Modic type II endplate degenerative changes seen at the apposing endplates of C6-C7.

Bone: Mild loss of vertebral body height of C5 and C6.

Bone marrow: Aside from degenerative changes no abnormal marrow signal is identified.

Discs: Varying degrees of disc desiccation involving C2-C3 down through C6-C7. Moderate associated loss of disc height seen at C5-C6 and C6-C7.

Findings at specific level:

Craniocervical junction and C1- C2: No significant finding seen in the craniocervical junction to the visualized extent.

C2- C3: A disc protrusion is identified. Spinal canal is patent. There is no significant narrowing of the bilateral neural foramen. Bilateral exiting nerve roots are normal. Disc deformity measures 2.0 mm.

C3- C4: A disc protrusion is identified. Disc material abuts the anterior aspect of the spinal cord and causes mild spinal canal narrowing. There is no abnormal signal within the spinal cord at this level. There is no significant narrowing of the bilateral neural foramen. Bilateral exiting nerve roots are normal. Annular fissure is identified. Disc deformity measures 2.6 mm.

C4- C5: A disc protrusion is identified. Spinal canal is patent. There is no significant narrowing of the bilateral neural foramen. Bilateral exiting nerve roots are normal. Annular fissure is identified. Disc deformity measures 2.3 mm.

C5- C6: A disc protrusion is identified. Disc material abuts the anterior aspect of the spinal cord and causes mild spinal canal narrowing. There is subtle increased signal within the spinal cord at this level which may reflect myelopathy in a proper clinical setting. Concurrent right uncovertebral joint hypertrophy is seen. Disc material and uncovertebral joint hypertrophy cause moderate right neural foraminal narrowing. Associated abutment on right exiting nerve root is seen. Annular fissure is identified. Disc deformity measures 2.7 mm.

C6- C7: A disc protrusion is identified. Disc material abuts the anterior aspect of the spinal cord and causes mild spinal canal narrowing. There is subtle increased signal within the spinal cord at this level which may reflect myelopathy in a proper clinical setting. Concurrent left uncovertebral joint hypertrophy is seen. Disc material and uncovertebral joint hypertrophy cause mild left neural foraminal narrowing. Bilateral exiting nerve roots are normal. Disc deformity measures 3.1 mm.

Report - SMITH PEPPER, A158209, 2022-10-25 19:21:00, A334088

Page 2 of 4

C7- T1: A disc protrusion is identified. Spinal canal is patent. There is no significant narrowing of the bilateral neural foramen. Bilateral exiting nerve roots are normal. Disc deformity measures 1.8 mm.

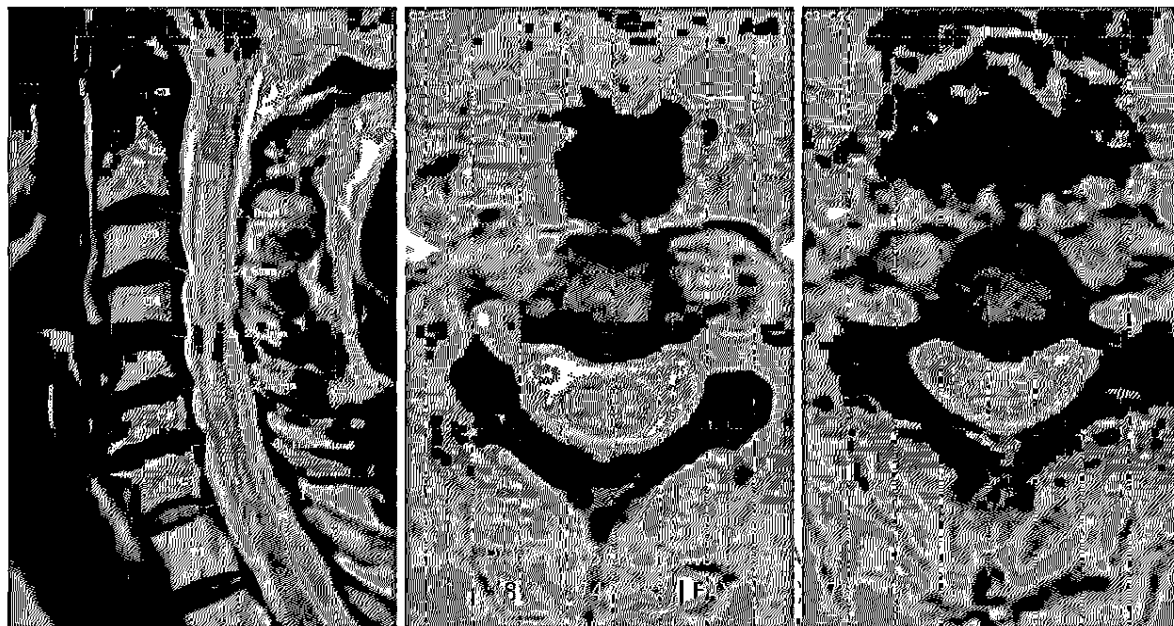
Impression:

1. Grade I posterior listhesis of C4 on C5.
2. Straightening of the cervical lordosis.
3. Modic type II endplate degenerative changes seen at the apposing endplates of C6-C7.
4. Mild loss of vertebral body height of C5 and C6.
5. Varying degrees of disc desiccation involving C2-C3 down through C6-C7. Moderate associated loss of disc height seen at C5-C6 and C6-C7.
6. C2-C3. A disc protrusion is identified. Disc deformity measures 2.0 mm.
7. C3-C4. A disc protrusion is identified. Disc material abuts the anterior aspect of the spinal cord and causes mild spinal canal narrowing. There is no abnormal signal within the spinal cord at this level. Annular fissure is identified. Disc deformity measures 2.6 mm.
8. C4-C5. A disc protrusion is identified. Annular fissure is identified. Disc deformity measures 2.3 mm.
9. C5-C6. A disc protrusion is identified. Disc material abuts the anterior aspect of the spinal cord and causes mild spinal canal narrowing. There is subtle increased signal within the spinal cord at this level which may reflect myelopathy in a proper clinical setting. Concurrent right uncovertebral joint hypertrophy is seen. Disc material and uncovertebral joint hypertrophy cause moderate right neural foraminal narrowing. Associated abutment on right exiting nerve root is seen. Annular fissure is identified. Disc deformity measures 2.7 mm.
10. C6-C7. A disc protrusion is identified. Disc material abuts the anterior aspect of the spinal cord and causes mild spinal canal narrowing. There is subtle increased signal within the spinal cord at this level which may reflect myelopathy in a proper clinical setting. Concurrent left uncovertebral joint hypertrophy is seen. Disc material and uncovertebral joint hypertrophy cause mild left neural foraminal narrowing. Disc deformity measures 3.1 mm.
11. C7-T1. A disc protrusion is identified. Disc deformity measures 1.8 mm.



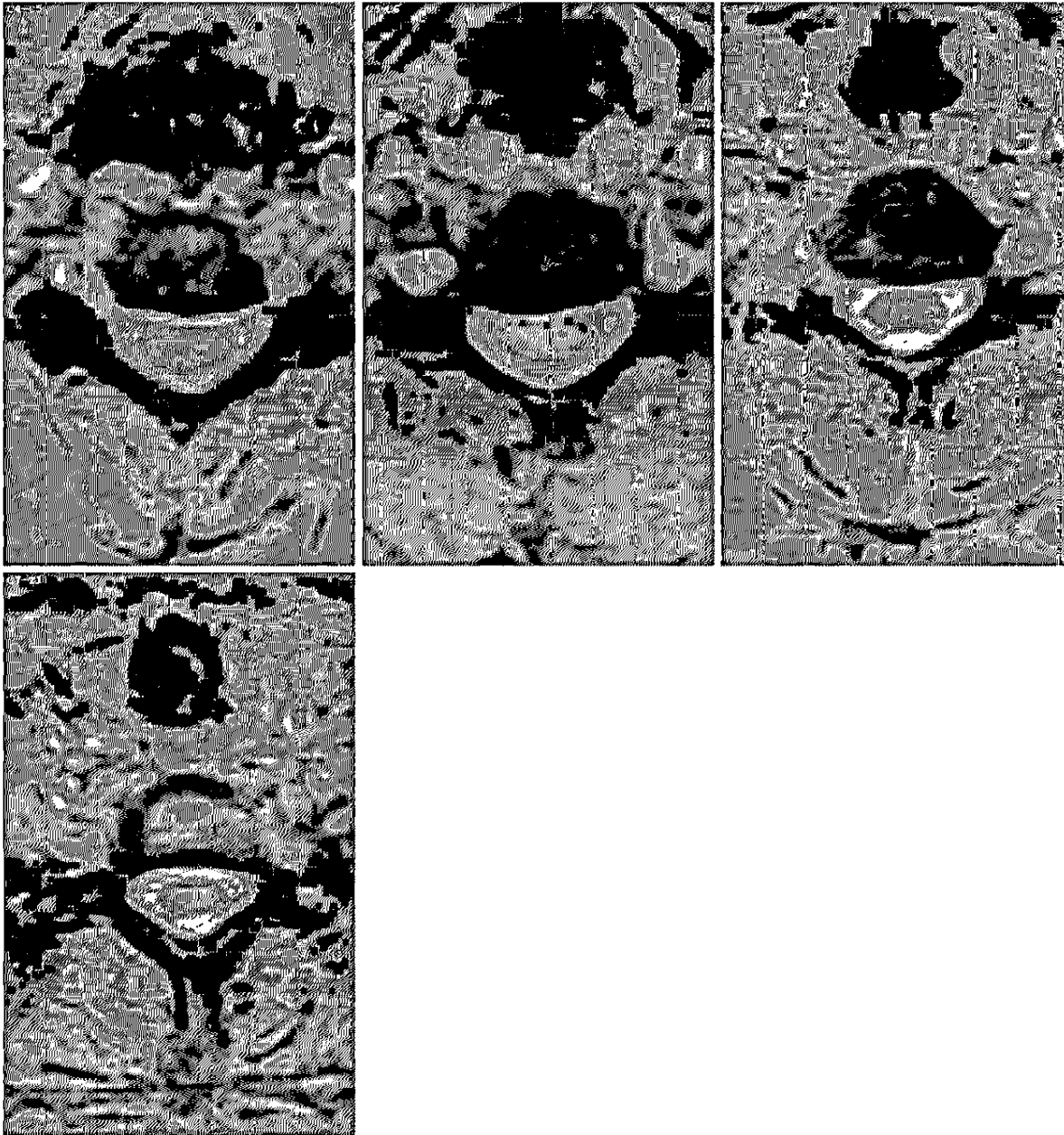
ANDREW THIERRY
RADIOLOGIST

Time Finalized: 2022-10-26 12:27:32



Report - SMITH PEPPER, A158209, 2022-10-25 19:21:00, A334088

Page 3 of 4



Report - SMITH PEPPER, A158209, 2022-10-25 19:21:00, A334088

Page 4 of 4

